
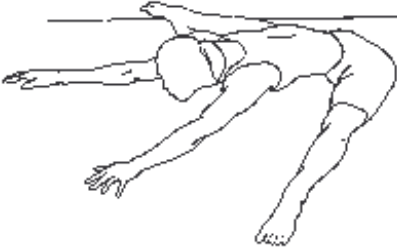

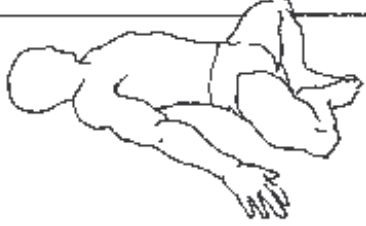

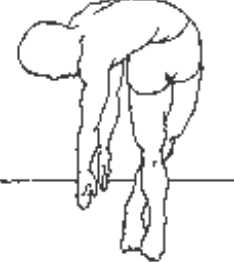
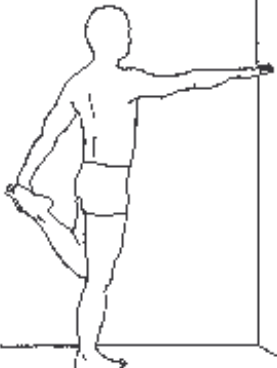

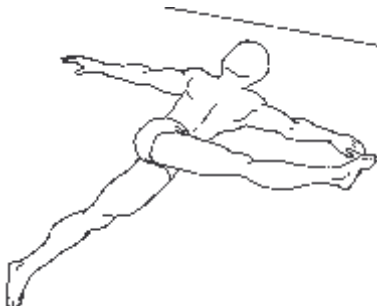
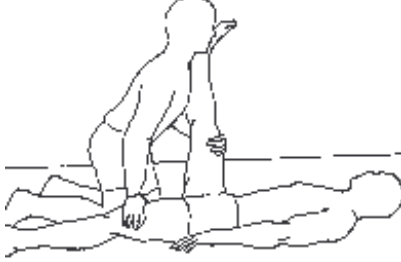
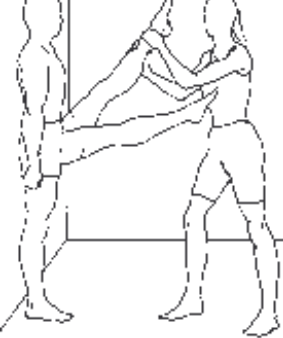



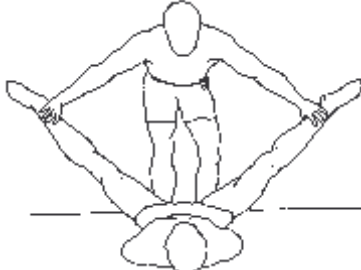
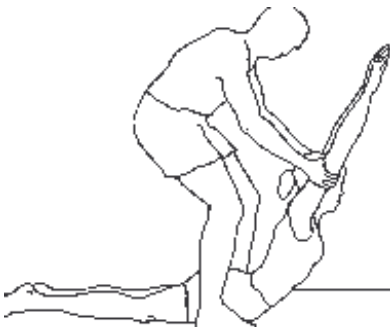
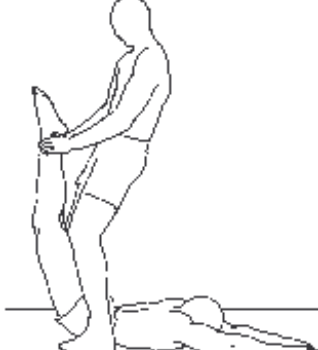
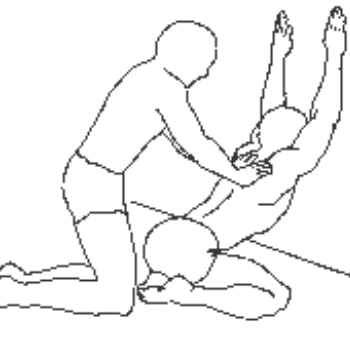
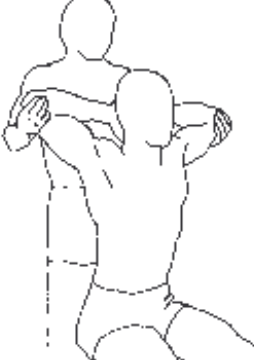
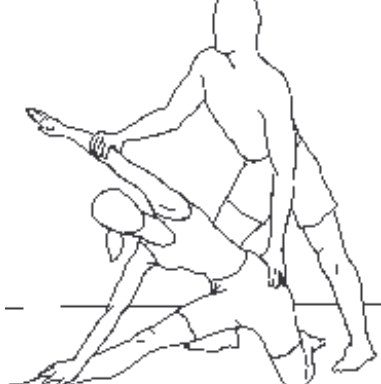
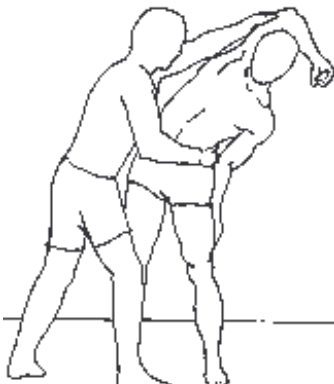
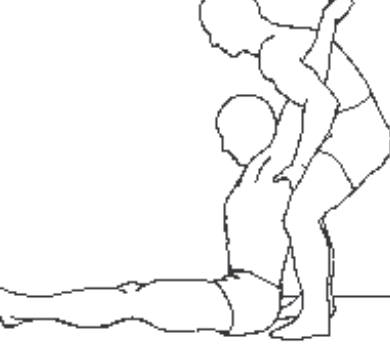
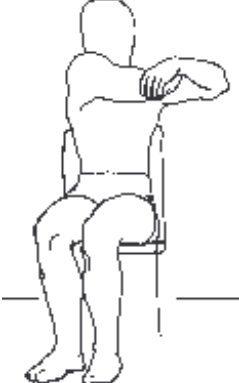
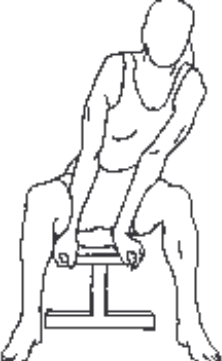


ISQUIOTIBIALS	QUADRÍCEPS	QUADRÍCEPS	ISQUIOTIBIALS
			
BESSONS	TIBIAL ANT-SOLEO	ISQUIOTIBIALS	GLUTIS
			
BESSONS	ADDUCTORS	ISQUIOTIBIALS	QUADRÍCEPS
			
TRAPECI-DORSAL	ABDOMINALS-OBLICS	ISQUIOTIBIALS	FLEXORS DEL CANELL
			
ISQUIOTIBIALS	BÍCEPS	ISQUIOTIBIALS	ISQUIOTIBIALS
			

QUADRÍCEPS – Vast extern – Vast intern – Sartori – Recte
 ISQUIOTIBIALS- Bíceps femoral – Semitendinós – Semimembranós
 BESSONS – Bessons – Soleo – Tendó d'aquiles

ADUCTORS-DORSAL	ADDUCTORS	ADDUCTORS
		
ADDUCTORS	ADDUCTORS	GLUTIS-ISQUIOS
		
QUADRÍCEPS	ADDUCTORS -DORSAL	GLUTIS
		
ISQUIOTIBIALS	ISQUIOTIBIALS	ISQUIOTIBIALS
		
ISQUIOTIBIALS - BESSONS	ISQUIOTIBIALS	ADDUCTORS
		

ABDOMINALS	LUMBAR	ABDOMINALS	GLUTIS
			
DORSAL AMPLE	ABDOMINALS	LUMBAR	ABDOMINALS
			
TRAPECI	DORSAL AMPLE	ABDOMINALS	TRAPECI-DORSAL A.
			
ESTERNOCLEIDOM.	PECTORAL-DELTOIDES	TRAPECI	PECTORALS
			
DELTOI-PECTORAL	DORSAL-OBLICS	PECTORALS	ESCALENO-TRAPECI
			

<p>ABDOMINALS (alts)</p>	<p>ABDOMINALS (baixos)</p>	<p>PECTORALS</p>
		
<p>PECTORALS</p>	<p>DELTOIDES-DORSAL</p>	<p>DORSAL AMPLE</p>
		
<p>DELTOIDES-REDONDO MY.</p>	<p>DELTOIDES</p>	<p>DELTOIDES</p>
		
<p>PECTORAL-ABDOMINAL</p>	<p>DELTOIDES-REDONDO MJ.</p>	<p>TRÍCEPS</p>
